



Contents lists available at ScienceDirect

Lung Cancer

journal homepage: www.elsevier.com/locate/lungcan

Case report

Histologic transformation of *EGFR* mutant lung adenocarcinoma without exposure to *EGFR* inhibitionTri Le^a, Joseph Sailors^b, Dwight H. Oliver^{b,c}, Melissa Mayer^c, Sharon Hoskin^c, David E. Gerber^{a,c,*}^a Department of Internal Medicine, University of Texas Southwestern Medical Center, Dallas, TX, United States^b Department of Pathology, University of Texas Southwestern Medical Center, Dallas, TX, United States^c The Harold C. Simmons Comprehensive Cancer Center, University of Texas Southwestern Medical Center, Dallas, TX, United States

ARTICLE INFO

Article history:

Received 6 October 2016

Received in revised form 6 December 2016

Accepted 4 January 2017

Keywords:

Squamous NSCLC

Adenocarcinoma NSCLC

EGFR

ABSTRACT

Resistance to *EGFR* kinase inhibitors appears to be invariable in the treatment of non-small cell lung cancer. Several mechanisms have been described. Here, we report the first case of histologic transformation of *EGFR* mutant lung adenocarcinoma without prior exposure to *EGFR* inhibition.

© 2017 Elsevier B.V. All rights reserved.

1. Introduction

Despite initial marked response to *EGFR* kinase inhibitors in patients with non-small cell lung cancer (NSCLC) harboring activating *EGFR* mutations, drug resistance develops within a median of 12 months. Described resistance mechanisms include secondary mutations within *EGFR* (e.g. T790M), *MET* amplification, PI3K pathway hyperactivation, *HER2* amplification, *AXL* overexpression, and epithelial-to-mesenchymal transition. Additionally, in rare cases, *EGFR* mutant lung adenocarcinoma may undergo histologic transformation to small cell lung cancer and squamous cell cancer after *EGFR* inhibitor treatment [1,2]. Here, we report the first case of histologic transformation of *EGFR* mutant lung adenocarcinoma without prior exposure to *EGFR* inhibition.

2. Case report

During radiographic evaluation of a stage 3A invasive ductal carcinoma of the right breast, a 79-year old woman with no smoking

history was found to have a right middle lobe mass (Fig. 1A). Biopsy demonstrated a TTF-1- and Napsin A-positive primary lung adenocarcinoma (Fig. 2A–C) harboring a classic *EGFR* exon 19 deletion (Fig. 3). She underwent right middle lobe lobectomy and mediastinoscopy, with a final diagnosis of stage 2 (T2N1M0) disease. The patient received three cycles of adjuvant carboplatin-pemetrexed chemotherapy (Fig. 1C). Subsequently she underwent partial right mastectomy, breast and axillary radiation therapy, and started tamoxifen.

Approximately 13 months after completing adjuvant chemotherapy, surveillance chest CT demonstrated an enlarging nodule at the right cardiophrenic angle (Fig. 1D). Biopsy revealed squamous cell carcinoma (Fig. 2E–F) with no evidence of adenocarcinoma histology. Molecular analysis demonstrated the original *EGFR* exon 19 deletion and no evidence of T790M mutation (Fig. 3). Immunohistochemical analysis of both the original and subsequent lung tumors demonstrated Rb expression (images not shown), suggesting absence of small cell histology. For both the original and subsequent lung tumors, all available tissue underwent histologic review. The patient initiated erlotinib, with partial response lasting six months (Fig. 1E).

3. Discussion

To our knowledge, this is the first reported case of histologic transformation of *EGFR* mutant lung adenocarcinoma without prior

* Corresponding author at: Division of Hematology-Oncology, Harold C. Simmons Comprehensive Cancer Center, University of Texas Southwestern Medical Center, 5323 Harry Hines Blvd., Mail Code 8852, Dallas, TX 75390-8852, United States.

E-mail addresses: david.gerber@utsouthwestern.edu, dru.gray@utsouthwestern.edu (D.E. Gerber).

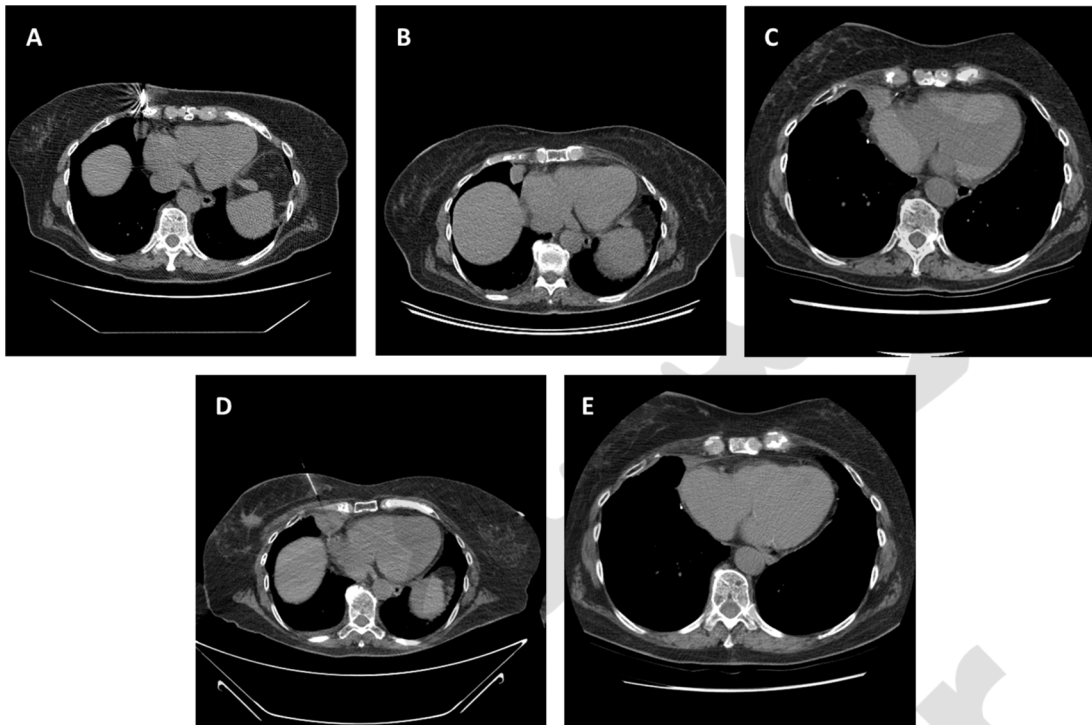


Fig. 1. A. Images from computed tomography (CT)-guided biopsy of adenocarcinoma lung lesion at the time of diagnosis. B. Chest CT before right middle lobectomy and adjuvant carboplatin-pemetrexed. C. Chest CT 5 months after right middle lobectomy and 1 month after last cycle of carboplatin-pemetrexed. D. CT-guided biopsy of squamous cell lung cancer progression. E. Images from chest CT 1 month after initiation of erlotinib with lesion now 1.9×0.8 cm, previously 2.4×2.0 cm.

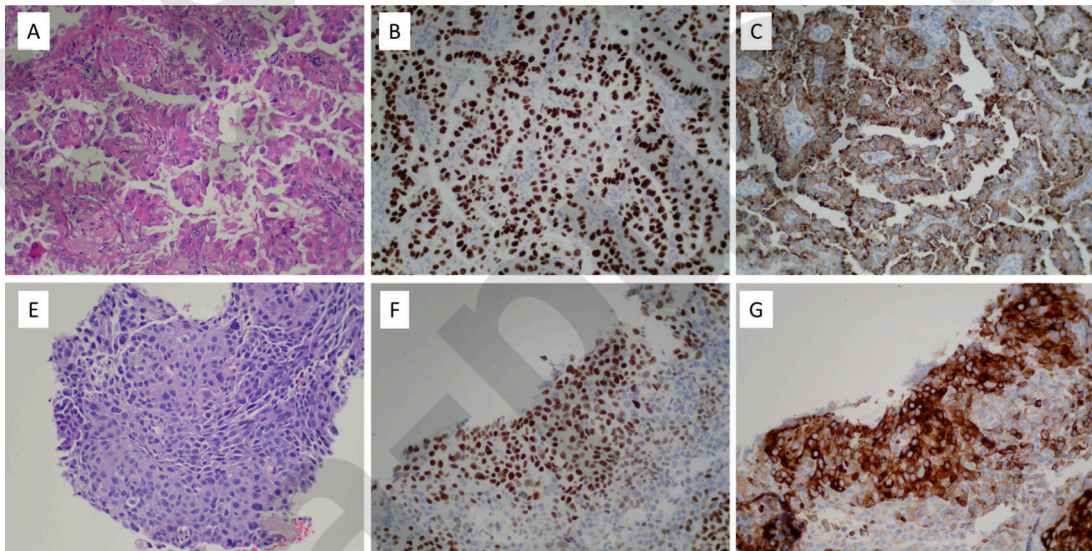


Fig. 2. A. Pulmonary adenocarcinoma, right middle lobe, H&E (200X). B. Pulmonary adenocarcinoma positive for TTF-1 (200X). C. Pulmonary adenocarcinoma positive for Napsin A (200X). Immunohistochemical stains for p63 and CK5/6 were negative (not shown). E. Squamous cell carcinoma, right cardiophrenic angle, H&E (200X). F. Squamous cell carcinoma positive for p63 (200X). G. Squamous cell carcinoma positive for CK5/6 (200X). An immunohistochemical stain for TTF-1 was negative (not shown).

exposure to EGFR inhibition. Potential explanations for the histologic transformation described in this case include (1) metaplastic transformation, (2) co-existence of both squamous and adenocarcinoma cells in the original tumor mass, or (3) development of a second primary cancer (unlikely given the maintenance of the original *EGFR* mutation). This phenomenon may suggest a population of pluripotent *EGFR* mutant cancer stem cells as the source of resistance. Although we observed morphological and immunohistochemical differences between the initial and recur-

rence specimens, we cannot rule out the possibility of a mixed tumor because needle biopsies provide limited sampling.

In this case, interval therapies included platinum-pemetrexed chemotherapy, breast irradiation, and the estrogen receptor modulator tamoxifen. Of these, pemetrexed seems the most likely to be associated with selective histologic pressure. Multiple clinical trials have demonstrated preferential efficacy of this agent against non-squamous tumors, which has been attributed to relatively greater expression and activity of thymidylate synthase in squamous cancers. The six-month duration of clinical benefit from EGFR inhibitor

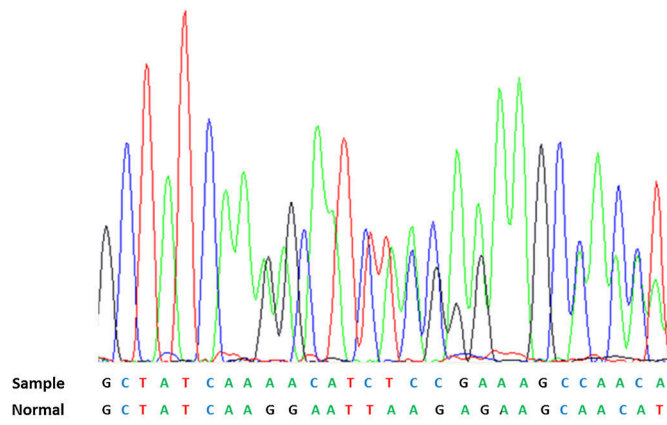


Fig. 3. Colored peaks of tumor DNA sequencing peaks correspond to the exon 19 DNA sequence indicated as sample. The reference normal sequence is below. The 15 nucleotides deleted in the sample (c2235_2249del) are underlined in the normal. There is no evidence of T790M deletion (not shown).

treatment of the squamous lung cancer in this case—approximately half the median duration observed in adenocarcinoma cases—is characteristic of *EGFR* mutant squamous cancers [3].

Recently, histologic transformation has also been reported in anaplastic lymphoma kinase (ALK)-positive NSCLC after ALK inhibitor treatment [4]. The present case suggests that lung cancers harboring driver mutations may undergo histologic transformation independent of exposure to kinase inhibitors. Whether these cases have greater propensity than pan-wild type tumors, or their molecular characterization permits a clearer distinction from second primaries, is not clear.

Conflict of interest statement

The authors report no conflicts of interest.

Acknowledgement

Funded in part by a National Cancer Institute Midcareer Investigator Award in Patient-Oriented Research (K24CA201543-01; to DEG).

Appendix A. Supplementary data

Supplementary data associated with this article can be found, in the online version, at <http://dx.doi.org/10.1016/j.lungcan.2017.01.005>.

References

- [1] P.A. Levin, M. Mayer, S. Hoskin, J. Sailors, D.H. Oliver, D.E. Gerber, Histologic transformation from adenocarcinoma to squamous cell carcinoma as a mechanism of resistance to EGFR inhibition, *J. Thorac. Oncol.* 10 (9) (2015) e86–e88.
- [2] L.V. Sequist, B.A. Waltman, D. Dias-Santagata, et al., Genotypic and histological evolution of lung cancers acquiring resistance to EGFR inhibitors, *Sci. Transl. Med.* 3 (75) (2011) 75ra26.
- [3] P. Graziano, F. de Marinis, B. Gori, et al., EGFR-driven behavior and intrapatient T790M mutation heterogeneity of non-small-cell carcinoma with squamous histology, *J. Clin. Oncol.* 33 (31) (2015) e115–e118.
- [4] S. Fujita, K. Masago, N. Katakami, Y. Yatabe, Transformation to SCLC after treatment with the ALK inhibitor alectinib, *J. Thorac. Oncol.* 11 (6) (2016) e67–e72.